



This is an enhanced PDF from The Journal of Bone and Joint Surgery

The PDF of the article you requested follows this cover page.

Surgical Treatment of Talar Body Fractures

Heather A. Vallier, Sean E. Nork, Stephen K. Benirschke and Bruce J. Sangeorzan
J Bone Joint Surg Am. 2004;86:180-192.

This information is current as of April 23, 2008

Reprints and Permissions

Click here to [order reprints or request permission](#) to use material from this article, or locate the article citation on [jbjs.org](#) and click on the [Reprints and Permissions] link.

Publisher Information

The Journal of Bone and Joint Surgery
20 Pickering Street, Needham, MA 02492-3157
[www.jbjs.org](#)

Surgical Treatment of Talar Body Fractures

Surgical Technique

By HEATHER A. VALLIER, MD, SEAN E. NORK, MD, STEPHEN K. BENIRSCHKE, MD, AND BRUCE J. SANGEORZAN, MD

Investigation performed at the Department of Orthopaedic Surgery, Harborview Medical Center, Seattle, Washington

The original scientific article in which the surgical technique was presented was published in JBJS Vol. 85-A, pp. 1716-1724, September 2003

ABSTRACT

BACKGROUND:

Fractures of the body of the talus are uncommon and poorly described. The purposes of the present study were to characterize these fractures, to describe one treatment approach, and to evaluate the clinical, radiographic, and functional outcomes of operative treatment.

METHODS:

Fifty-six patients with fifty-seven talar body fractures who had been treated operatively during a sixty-seven-month period at a level-1 trauma center were identified with use of a database. Twenty-three patients had a concomitant talar neck fracture. Eleven of the fifty-seven fractures were open. All patients underwent open reduction and internal fixation. Complications, secondary procedures, and the ability to return to work were evaluated at a minimum of one year. The radiographic presence of osteonecrosis and posttraumatic arthritis was ascertained.

continued

INTRODUCTION

Fractures of the talar body are uncommon injuries, which frequently have a poor prognosis. Accurate articular reduction will restore congruity of the tibiotalar and subtalar joints. Rigid internal fixation may provide stability to promote early mobility of these joints. Surgical

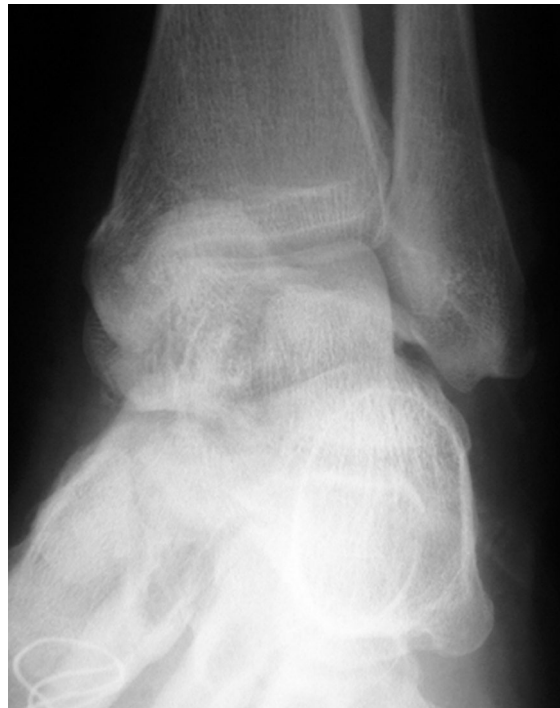

FIG. 1-A

Anteroposterior (Fig. 1-A) and lateral (Fig. 1-B) plain radiographs of an open fracture of the talar body in a thirty-four-year-old woman who sustained the injury in a high-speed motor-vehicle accident.

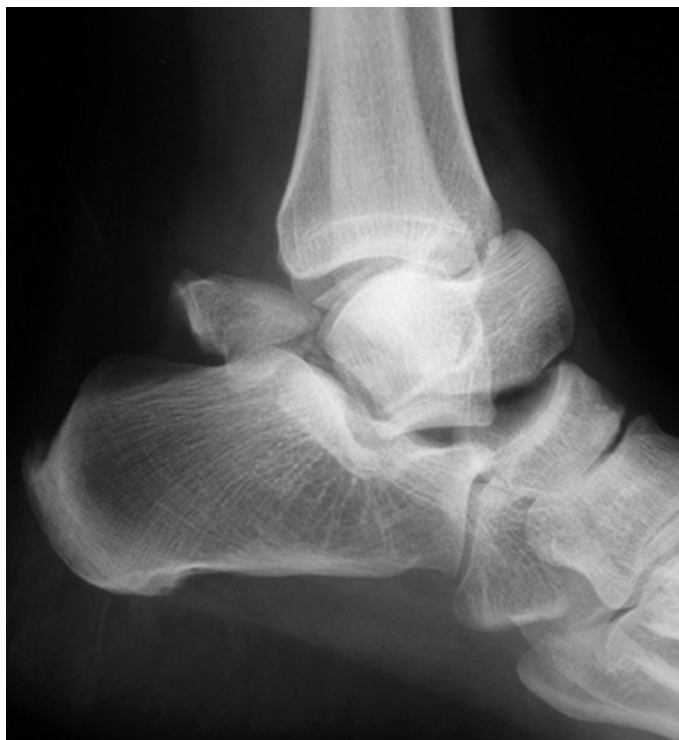

FIG. 1-B

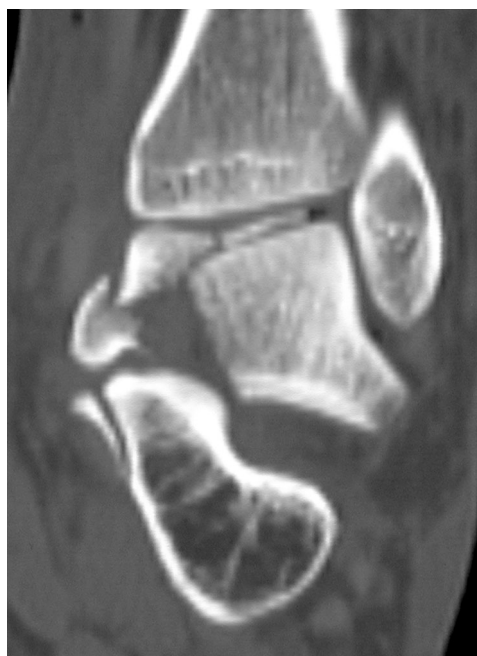

FIG. 1-C

A computerized tomography scan provides additional information about the locations and sizes of the fracture fragments for preoperative planning.

ABSTRACT | continued

Foot Function Index and Musculoskeletal Function Assessment questionnaires were completed.

RESULTS:

Thirty-eight patients were evaluated after an average duration of follow-up of thirty-three months. Early complications occurred in eight patients. Ten of the twenty-six patients who had a complete set of radiographs had development of osteonecrosis of the talar body. Five of these ten patients experienced collapse of the talar dome at a mean of 10.2 months after surgery. All patients with a history of both an open fracture and osteonecrosis experienced collapse. Seventeen of twenty-six patients had posttraumatic arthritis of the tibiotalar joint, and nine of twenty-six had posttraumatic arthritis of the subtalar joint. Fractures of both the talar body and neck led to development of advanced arthritis more frequently than did fractures of the talar body only ($p = 0.04$). All patients with open fractures had end-stage posttraumatic arthritis ($p = 0.053$). Twenty-three (88%) of twenty-six patients had radiographic evidence of osteonecrosis and/or posttraumatic arthritis. Worse outcomes were noted in association with comminuted and open fractures. Osteonecrosis and posttraumatic arthritis adversely affected outcome scores.

CONCLUSIONS:

Open reduction and internal fixation of talar body fractures may restore congruity of the adjacent joints. However, early complica-

continued

ABSTRACT | continued

tions are not infrequent, and most patients have development of radiographic evidence of osteonecrosis and/or post-traumatic arthritis. Associated talar neck fractures and open fractures more commonly result in osteonecrosis or advanced arthritis. Worse functional outcomes are seen in association with advanced posttraumatic arthritis and osteonecrosis that progresses to collapse. It is important to counsel patients regarding these devastating injuries and their poor prognosis and potential complications.

treatment, with these goals in mind, may optimize foot and ankle function.

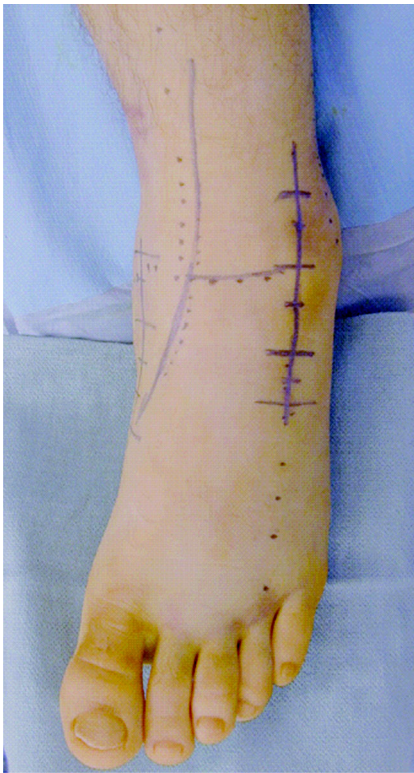
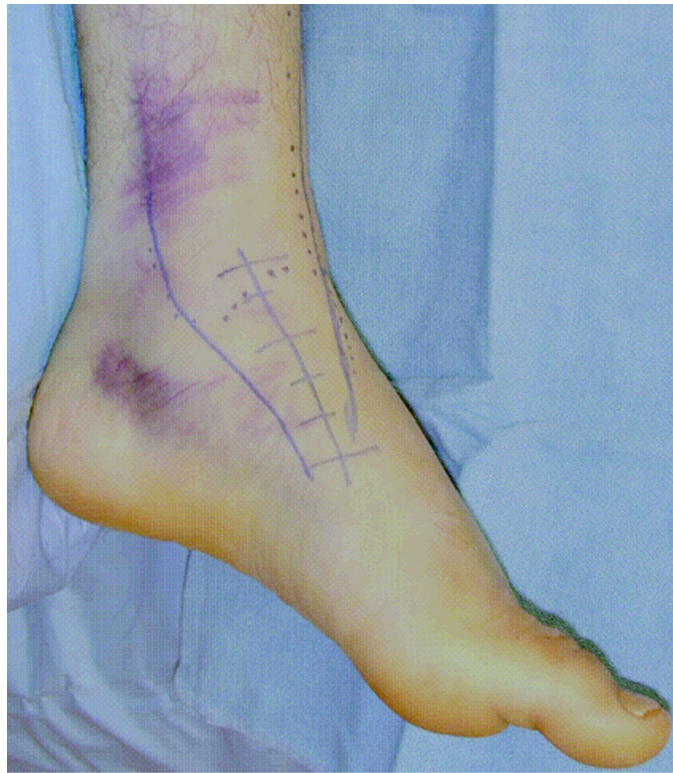SURGICAL TECHNIQUE

The initial management consists of urgent treatment of open injuries and dislocations. Open wounds are irrigated, and sterile dressings are applied. Intravenous antibiotics and tetanus prophylaxis are administered. Reduction maneuvers are performed to improve fracture alignment whenever possible, and provisional splints are applied.

Preoperative plain radiographs, including anteroposterior, oblique, and lateral views

of the foot and anteroposterior, mortise, and lateral views of the ankle, are made. Computerized tomography scans are done for severely comminuted fractures, to assist in preoperative planning. Axial images through the tibiotalar and subtalar joints are obtained, and computer reconstructions in the sagittal and coronal planes are generated (Figs. 1-A, 1-B, and 1-C).

Irrigation and débridement of open fractures and open reduction of irreducible dislocations are undertaken on an urgent basis. Definitive reduction and fixation of these injuries may be performed during the

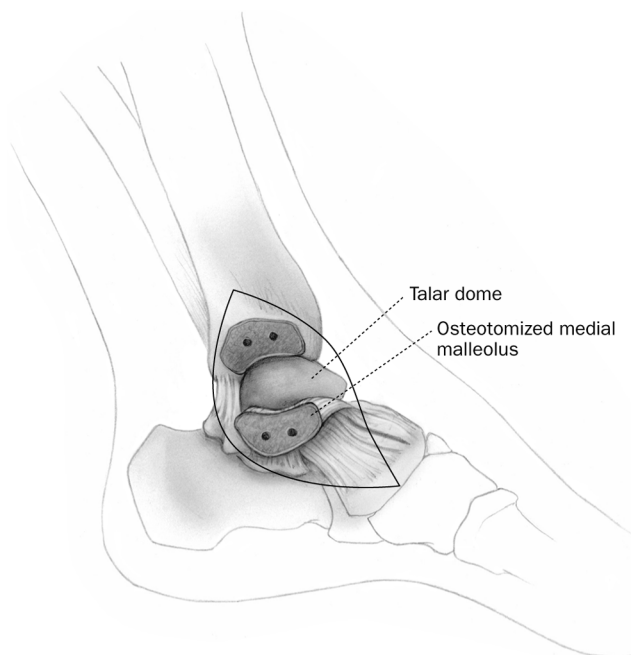
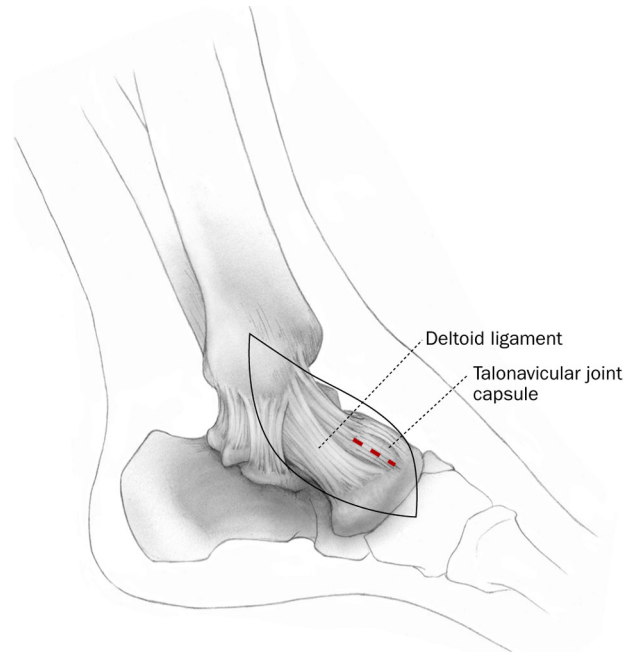
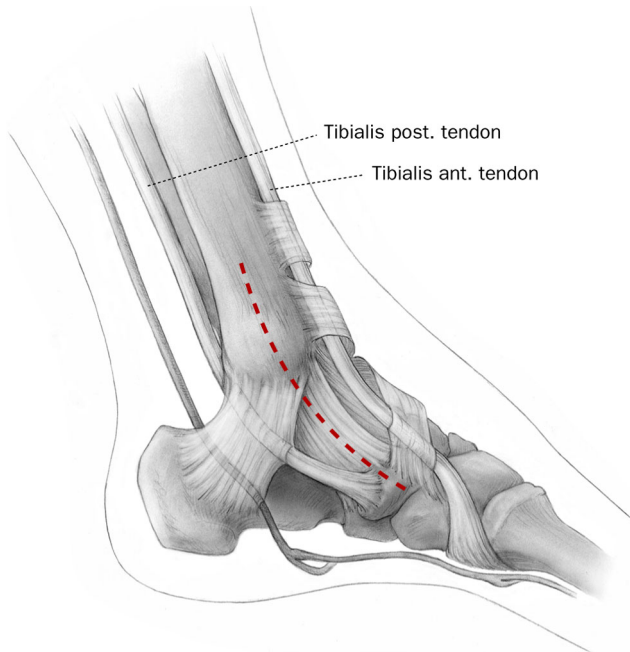
**FIG. 2-A****FIG. 2-B**

Clinical photographs depicting the anteromedial and anterolateral surgical approaches, which may be used alone or in combination to treat fractures of the talar body.

same anesthesia session. Occasionally, the safe completion of surgical care is precluded by associated life-threatening injuries, severe soft-tissue swelling, or the need for additional

radiographic information. In such situations temporary Kirschner wire fixation, spanning external fixation, and/or splinting may be performed. In these cases, and in the treatment

of high-energy closed fractures, surgical delay is recommended to allow soft-tissue swelling to decrease. Delays of several days to as long as three weeks may be necessary before definitive sur-



FIGS. 2-C, 2-D, and 2-E

The medial approach.

CRITICAL CONCEPTS**INDICATIONS:**

- All talar body fractures with >1 mm of articular displacement.

CONTRAINDICATIONS:

- Severe soft-tissue swelling or fracture blisters.
- Extensive open fracture wounds that limit access to the fracture (Fig. 10).
- Severely contaminated open fracture wounds.

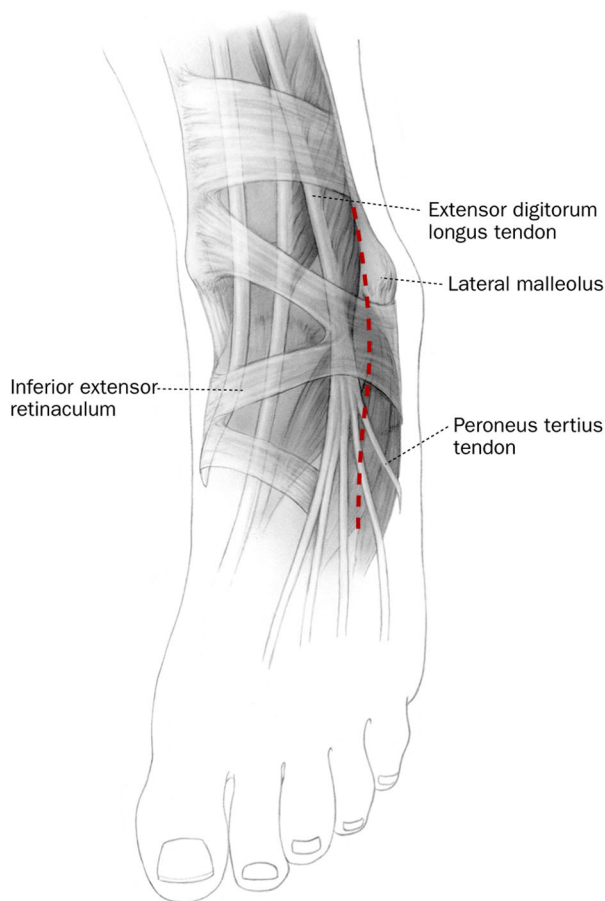
continued

gical treatment is attempted.

Isolated, simple, sagittal fractures of the talar body may be approached through a single medial or lateral incision, depending on the fracture location. A large portion of the talar dome can be exposed with plantar flexion of the foot. Talar body fractures with coronal displacement, comminution, or an associated talar neck fracture are most accurately addressed through dual antero-medial and anterolateral surgical approaches (Figs. 2-A through 2-

G)¹⁻³. Adjuvant osteotomies of the medial malleolus^{3,4} or of the distal part of the fibula may be necessary to enhance the exposure.

The patient is positioned supine on a radiolucent operating table. The incision for the anteromedial surgical approach extends from the anterior aspect of the medial malleolus to the navicular and is centered approximately between the tibialis anterior and tibialis posterior tendons (Figs. 2-B and 2-C). The intact fibers of the deltoid liga-

**FIG. 2-F**

The lateral approach.

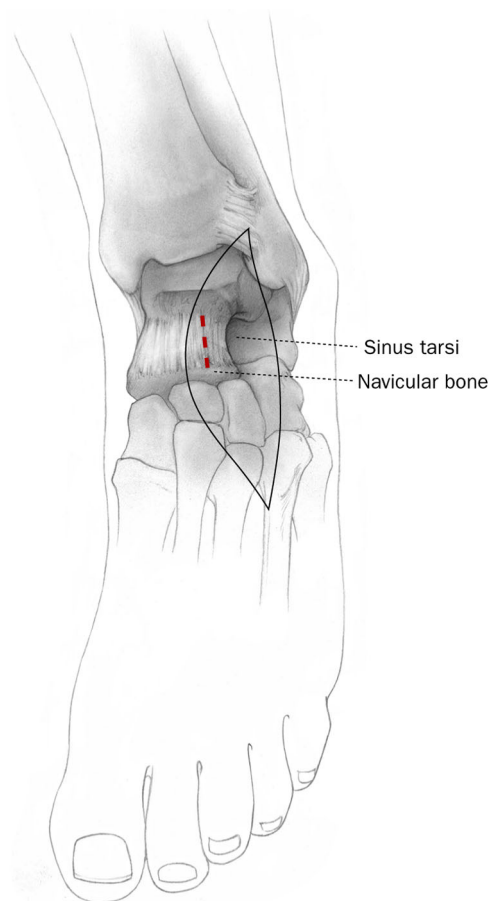
**FIG. 2-G**

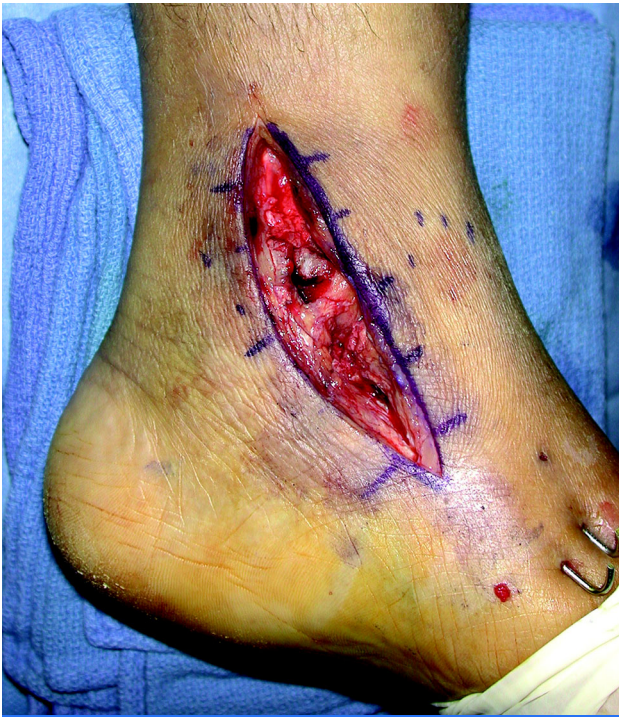

FIG. 3-A

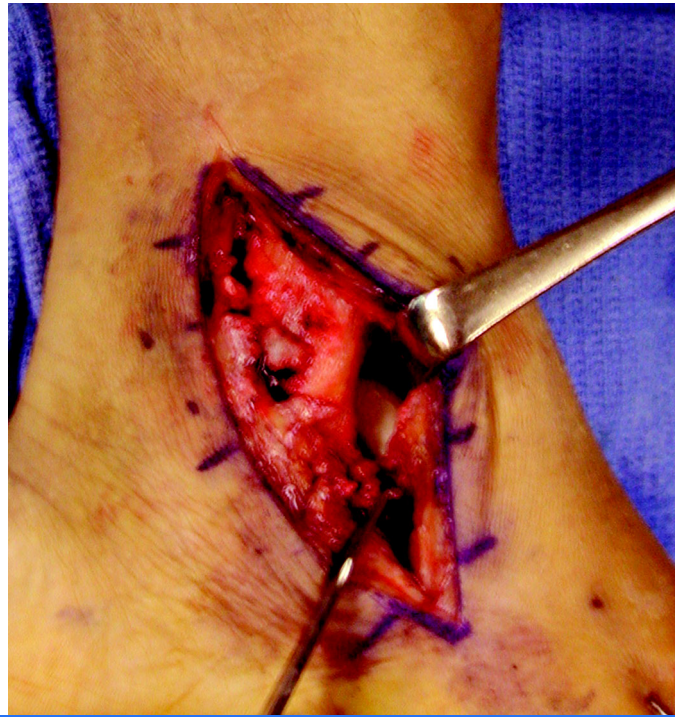


FIG. 3-B

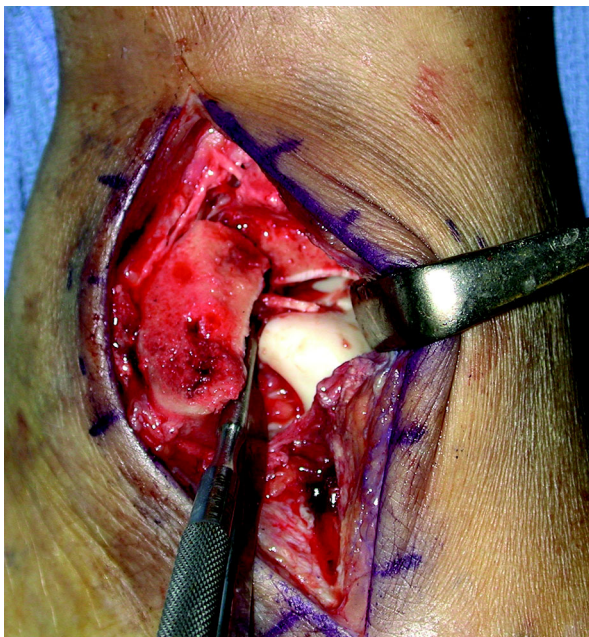


FIG. 3-C

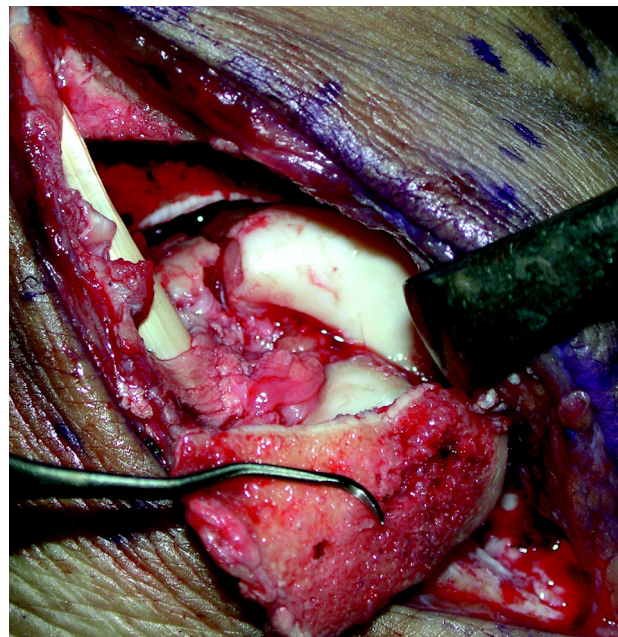
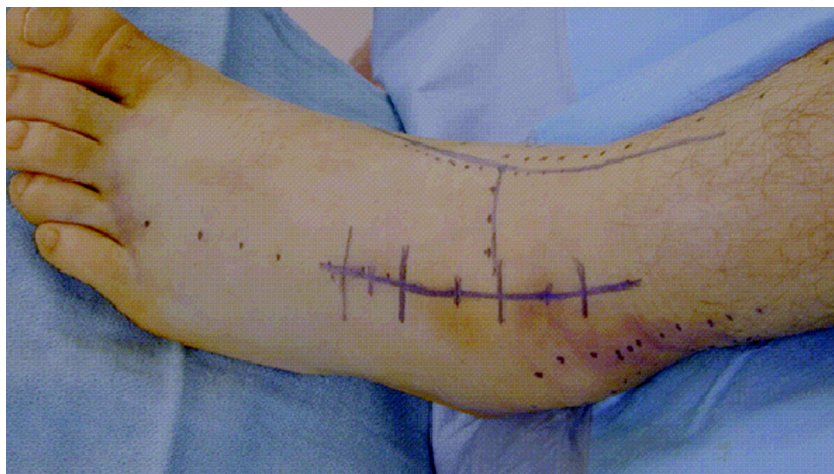
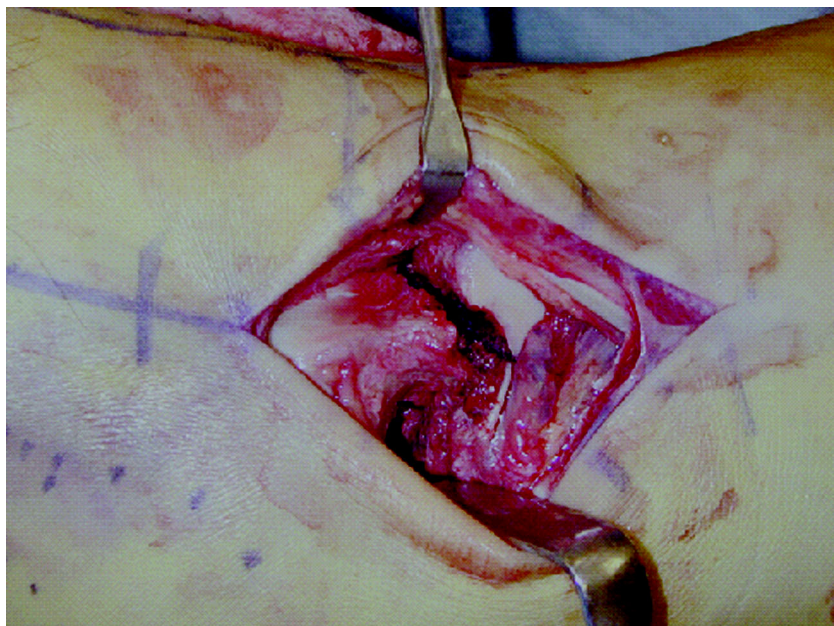

FIG. 3-D

Intraoperative photographs demonstrate an anteromedial approach (Fig. 3-A). There is minimal access to the medial aspect of the talar body before a medial malleolar osteotomy is performed (Fig. 3-B). The osteotomized medial malleolus is reflected inferiorly (Fig. 3-C), greatly enhancing visualization of the fracture (Fig. 3-D).

CRITICAL CONCEPTS | continued**PITFALLS:**

- Dissection should strictly follow the described anatomic landmarks. The dorsalis pedis artery supplies the soft tissue between the two anterior surgical incisions. We have not observed any compromise of the integrity of this soft-tissue bridge or the overlying skin; however, we recommend sharp dissection with maintenance of full-thickness flaps.
- Care must be taken to avoid any unnecessary surgical dissection that may compromise the remaining talar blood supply.
- The integrity of the deltoid ligament should be respected, and inferior dissection anterior to the deltoid ligament should be avoided.
- While an adjunctive medial malleolar osteotomy may improve visualization of the articular surface of the talar body, nonunion of the medial malleolus is possible. Use of a thin saw, predrilling, and accurate reduction in compression should help to prevent this complication. An osteotome should be used to complete the osteotomy, ensuring that the morphology of the medial articular shoulder of the distal part of the tibia is maintained.
- Prominent screw heads on the articular surface can cause irritation of the joint. Care should be taken to countersink these screws.

continued**FIG. 4-A****FIG. 4-B**

The anterolateral approach to the talus.

ment are protected, and plantar dissection is avoided to protect any remaining talar blood supply from the branches of the posterior tibial artery. The talonavicular joint capsule is sharply incised, and the dorsomedial aspect of the talar neck is exposed. The medial aspect of the ante-

rior surface of the talar body can now be viewed. Frequently, a medial malleolar osteotomy is required to gain access to the middle and posterior portions of the medial part of the talar body for accurate reduction and fixation. This osteotomy is inclined obliquely and is performed after

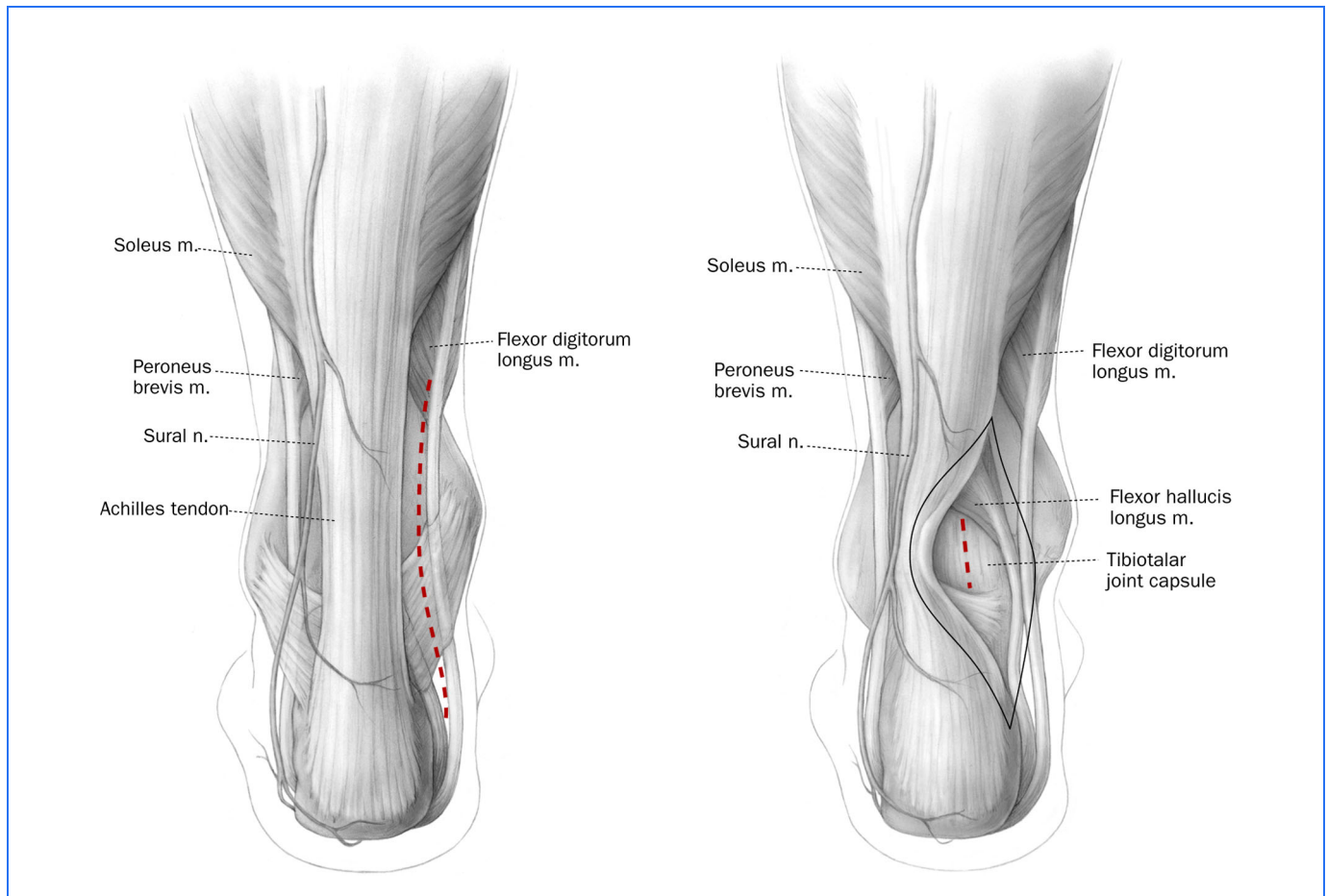


FIG. 5-A

FIG. 5-B

The posteromedial approach to the talar body.

predrilling two parallel holes with a 2.5-mm drill bit. The osteotomy is initiated with a microsagittal saw and is completed with a thin osteotome, to fracture the subchondral bone and cartilage. The cut surfaces are irrigated while the saw is used, in order to prevent thermal necrosis of the bone. The adjacent posterior neurovascular structures and the tibialis posterior tendon are protected. The medial malleolus is then retracted distally, allowing visualization of the medial portion of the talar body (Figs. 3-A through 3-D).

The incision for the antero-lateral approach is centered at the ankle joint, is parallel to the fourth metatarsal distally, and is parallel to and between the tibia and fibula proximally (Fig. 2-A). Because of the need to retract the anterior compartment tendons, the incision is extended proximal to the ankle joint. The incision terminates slightly distal to the predicted location of the talonavicular joint. Dissection through the skin and the subcutaneous tissues should proceed sharply, and full-thickness skin flaps should be maintained.

The superficial peroneal nerve may cross the surgical field proximally. It should be identified, mobilized, and protected throughout the procedure. The fascia over the anterior compartment of the distal part of the tibia is incised sharply, and the extensor retinaculum is incised. The entire anterior compartment, including the peroneus tertius, can then be mobilized and retracted medially. The fat in the sinus tarsi is excised, and the extensor digitorum brevis is elevated and retracted inferiorly. The lateral aspect of the

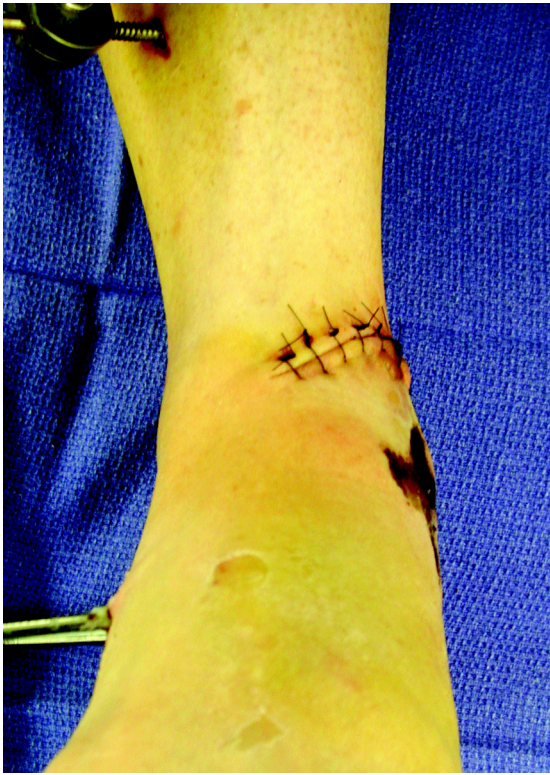

FIG. 6-A

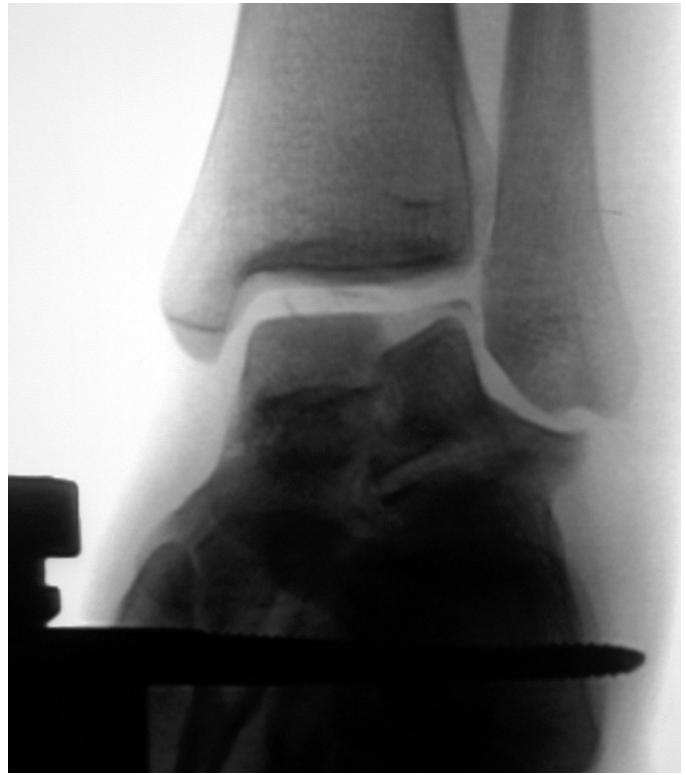

FIG. 6-B

Schanz pins placed in the distal aspect of the tibia and in the calcaneus (Fig. 6-A) may provide provisional or adjunctive fixation. Intraoperatively, the application of a femoral distractor (Fig. 6-B) enhances visualization and indirect reduction.

talar neck and the lateral process of the talus are exposed, and the lateral aspects of the talar body and dome can now be visualized (Figs. 4-A and 4-B). The talar head is exposed after the lateral talonavicular joint capsule is incised. Occasionally, an osteotomy of the distal part of the fibula is required to gain access to the lateral and posterior portions of the lateral aspect of the talar body for accurate reduction and fixation.

Isolated fractures of the posteromedial aspect of the talar body are best approached through a posteromedial incision (Figs. 5-A and 5-B). The patient

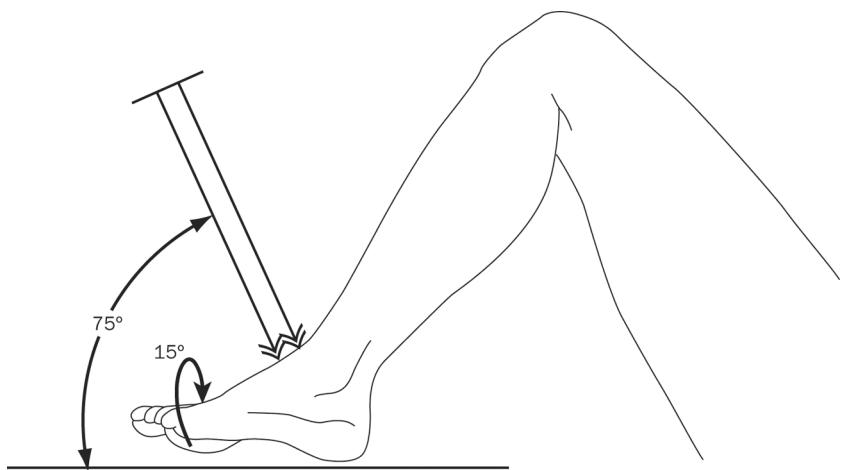
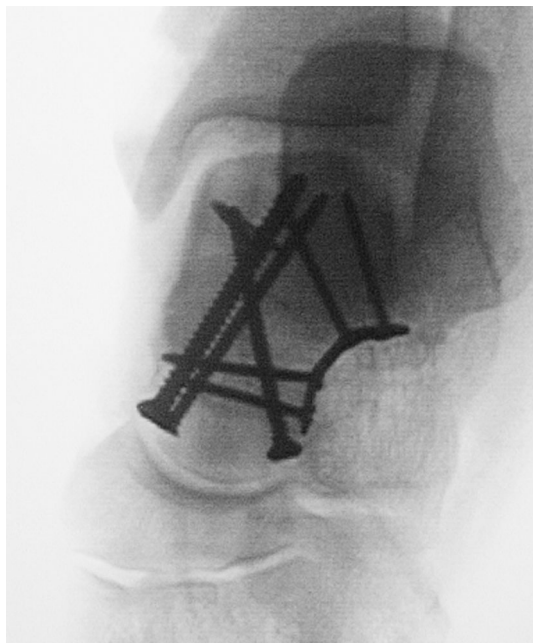


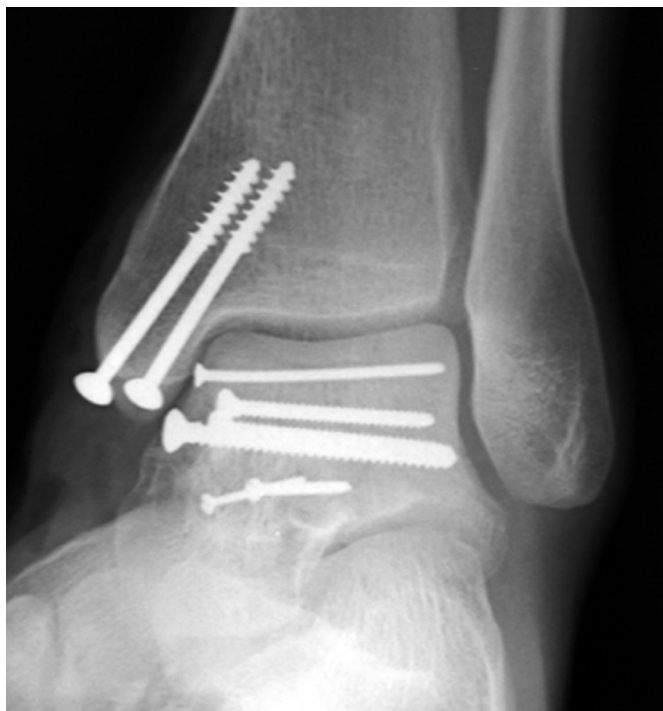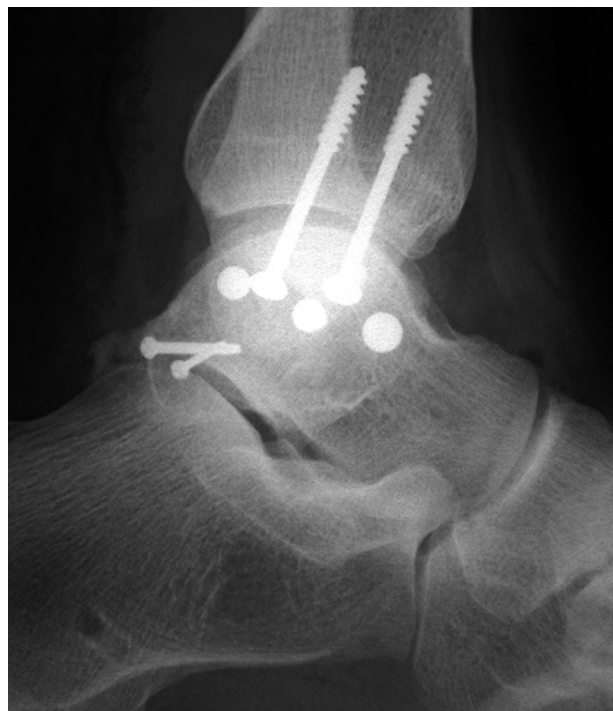FIG. 7-A

A drawing depicting the technique of obtaining the talar neck view described by Canale and Kelly⁵.

**FIG. 7-B**

An intraoperative view described by Canale and Kelly displays the axial alignment of the talus.

is positioned either prone or supine. When the patient is in the supine position, a bump is placed beneath the contralateral hip, promoting external rotation of the affected lower extremity. The incision is curvilinear and is centered halfway between the posterior aspect of the medial malleolus and the medial edge of the Achilles tendon, approximately 3 cm proximal to the distal aspect of the medial malleolus. It can be extended distally and anteriorly, along the course of the toe flexors. The deep fascia and retinaculum are incised. The deep dissection can be through the interval between the flexor digitorum longus and the

**FIG. 8-A****FIG. 8-B**

Postoperative anteroposterior (Fig. 8-A) and lateral (Fig. 8-B) plain radiographs made after open reduction and internal fixation of a medial talar body fracture. An adjunctive osteotomy of the medial malleolus was performed.

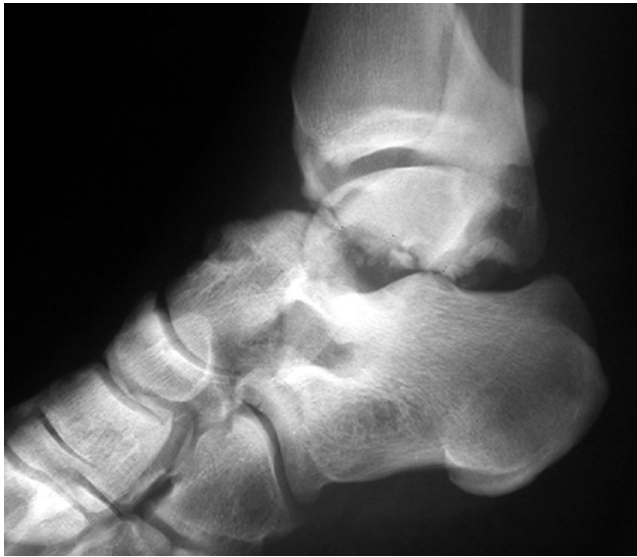

FIG. 9-A

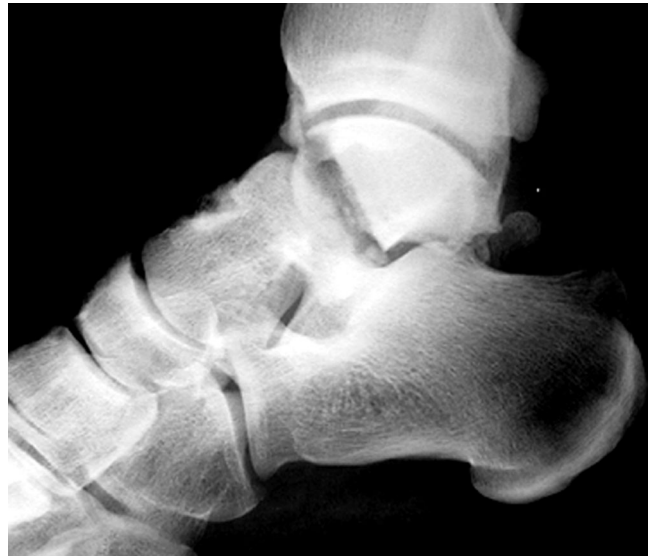

FIG. 9-B

Injury radiograph of a talar body fracture-dislocation (Fig. 9-A), which was treated with urgent closed reduction (Fig. 9-B).

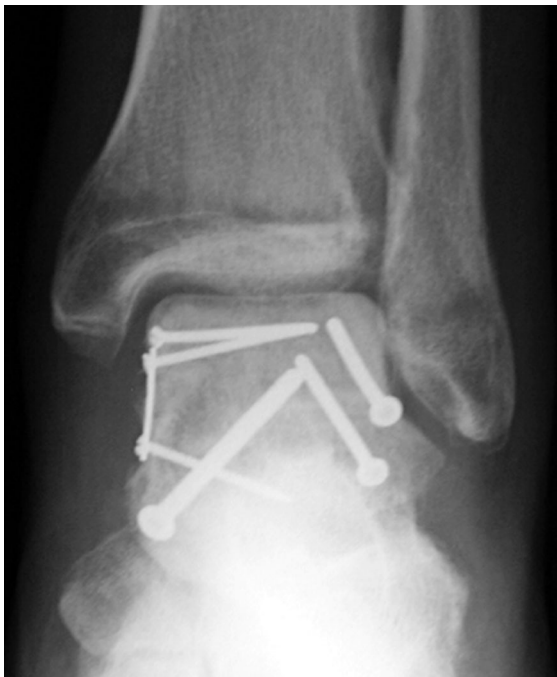

FIG. 9-C

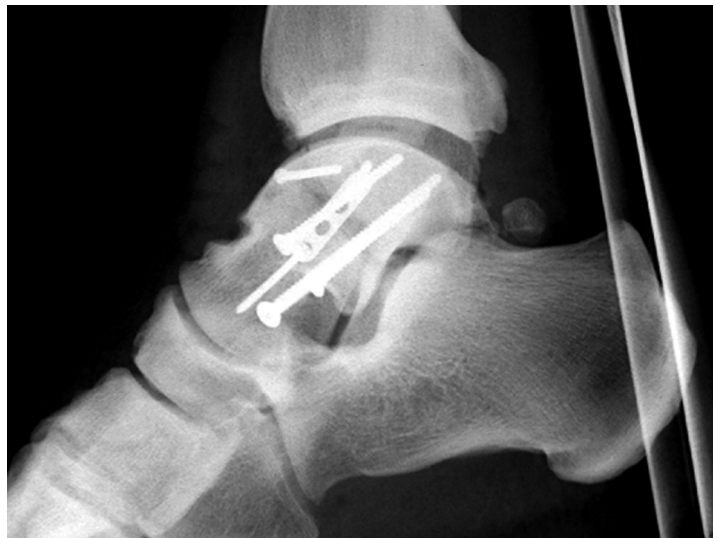
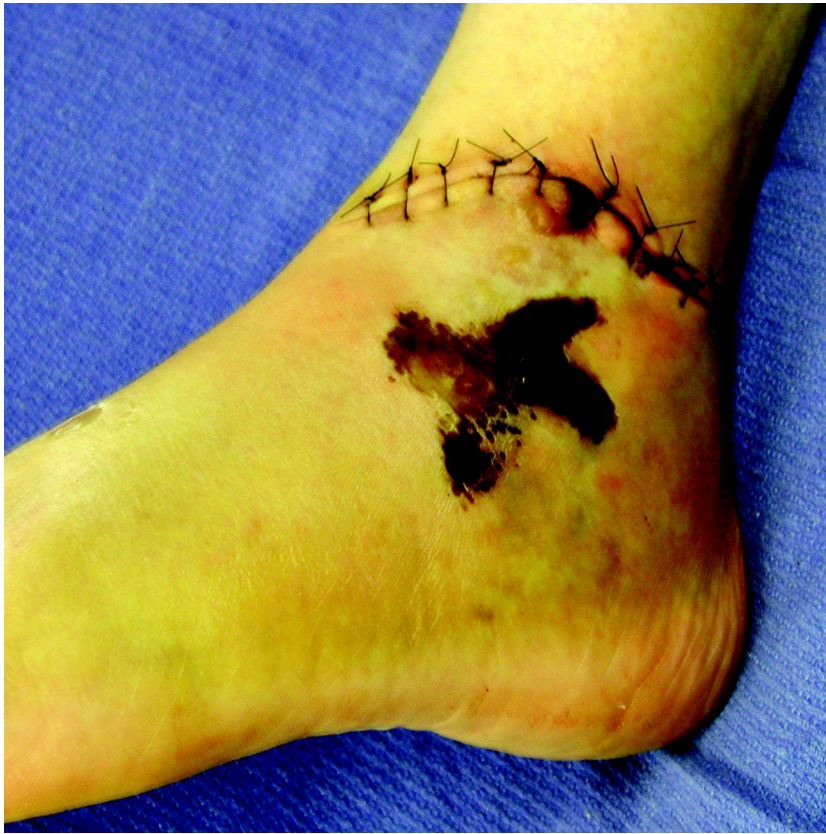
FIG. 9-D

Open reduction and internal fixation was performed through dual anteromedial and anterolateral approaches. The cortex of the lateral process/talar neck was used to seat two of the major fixation screws.

**FIG. 10**

Because of the irregular lateral traumatic wound and severe soft-tissue damage associated with a high-energy fracture of the talar body and neck, access through a lateral surgical approach was not possible.

tibial neurovascular bundle, or posterior to the flexor hallucis longus. The location for the deep dissection is dictated by the pattern of the articular fracture. The tibiotalar joint capsule is incised longitudinally, and the fracture is exposed.

Intraoperative exposure and indirect fracture reduction may be facilitated by the use of a small femoral distractor, which is employed to tension the soft tissues and open the ankle joint (Figs. 6-A and 6-B). Schanz pins are placed at sites remote from the

injury, frequently in the distal part of the tibial shaft, the calcaneus, and/or the navicular. Headlamp illumination is helpful for visualization. The fractures are reduced, and provisional Kirschner wires are placed. The alignment is assessed with intraoperative fluoroscopy. The tibiotalar joint is best seen with the lateral and mortise ankle views, and the subtalar joint is best seen with the lateral and 45° mortise views. The axial alignment of the talar neck can be further assessed with the talar neck view described

by Canale and Kelly⁵ (Figs. 7-A and 7-B).

Definitive internal fixation is performed with small-fragment and mini-fragment implants. Small articular fracture fragments are best stabilized with 2.4, 2.0, and 1.5-mm screws (Figs. 8-A and 8-B). These cruciform screw heads are flat, allowing placement beneath the cartilage surface after counter-sinking. In fractures isolated to the talar body, the lateral process of the talus is usually intact and in continuity with the distal fragment, which includes the head and neck of the talus. This permits placement of screws in an extra-articular location from the firm cortical bone of the lateral aspect of the talar neck into the posterior part of the talar body (Figs. 9-A through 9-D). Sagittal plane articular fractures of the talar body typically require fixation from medial to lateral with lag screws. After a medial malleolar osteotomy is performed, these implants are inserted through the medial aspect of the talar body. Small osteochondral fragments are best fixed with individual screws (2.0 or 1.5 mm), which anchor into stable portions of the talus. It has been our preference to use metal implants. Biodegradable implants may be a reasonable option for the fixation of small osteochondral fragments, but we do not have experience with them. Small-fragment screws and/or mini-fragment plates and screws are used to rigidly stabilize an associated talar neck fracture¹.

CRITICAL CONCEPTS | continued**AUTHOR UPDATE:**

The surgical techniques have not been altered since the original article was published.

Bone-grafting is recommended for closed fractures with defects in the talar neck. Morselized cancellous allograft chips and cancellous bone from the ipsilateral calcaneal tuberosity are both effective.

The wounds are closed over small suction drains. A modified Donati-Allgower suture technique is employed to dissipate tension on the skin edges⁶. The ankle and foot are splinted in neutral alignment until the wounds are sealed and the soft-tissue swelling has decreased. Range-of-motion exercises of the ankle and foot are then initi-

ated. Spanning external fixation is used as an adjunct to internal fixation in cases of severe fracture comminution or bone loss. The external fixators are removed in the outpatient clinic after approximately six weeks. No weight-bearing is permitted for twelve weeks postoperatively or until fracture union.

Heather A. Vallier, MD
Department of Orthopaedic Surgery, MetroHealth Medical Center, 2500 MetroHealth Drive, Cleveland, OH 44109. E-mail address: heathervallier@yahoo.com

Sean E. Nork, MD
Stephen K. Benirschke, MD
Bruce J. Sangeorzan, MD
Department of Orthopaedic Surgery, Harborview Medical Center, Box 359798, 325 Ninth Avenue, Seattle, WA 98104-2499

The authors did not receive grants or outside funding in support of their research or preparation of this manuscript. They did not receive payments or other benefits or a commitment or agreement to provide such benefits from a commercial entity. No commercial entity paid or directed, or agreed

to pay or direct, any benefits to any research fund, foundation, educational institution, or other charitable or nonprofit organization with which the authors are affiliated or associated.

The line drawings in this article are the work of Joanne Haderer Müller of Haderer & Müller (biomedart@haderermuller.com).

REFERENCES

1. **Fleuriau Chateau PB, Brokaw DS, Jelen BA, Scheid DK, Weber TG.** Plate fixation of talar neck fractures: preliminary review of a new technique in twenty-three patients. *J Orthop Trauma.* 2002;16:213-9.
2. **Mayo KA.** Fractures of the talus: principles of management and techniques of treatment. *Tech Orthop.* 1987;2:42-54.
3. **Thordarson DB.** Talar body fractures. *Orthop Clin North Am.* 2001;32:65-77.
4. **Ziran BH, Abidi NA, Scheel MJ.** Medial malleolar osteotomy for exposure of complex talar body fractures. *J Orthop Trauma.* 2001;15:513-8.
5. **Canale ST, Kelly FB Jr.** Fractures of the neck of the talus. Long-term evaluation of seventy-one cases. *J Bone Joint Surg Am.* 1978;60:143-56.
6. **White RR, Babikian GM.** Tibia: shaft. In: Ruedi TP, Murphy WM, editors. *AO principles of fracture management.* New York: Thieme; 2000. p 525-6.